

# Obturator Nerve Entrapment

## A Cause of Groin Pain in Athletes

Chris Bradshaw, FACSP, Paul McCrory,\* FRACP FACSP FACSM, Simon Bell, FRACS, and Peter Brukner, FACSP FACSM

*From the Olympic Park Sports Medicine Centre, Melbourne, Australia*

### ABSTRACT

Chronic groin pain in athletes is often difficult to diagnose and treat. There are many anatomic structures in the inguinal and groin region that have the potential to cause pain. We report 32 cases of a previously undescribed condition in athletes of "obturator neuropathy," a fascial entrapment of the obturator nerve where it enters the thigh. This condition represents a type of groin pain in athletes that is treatable by surgical means. There is a characteristic clinical pattern of exercise-induced medial thigh pain commencing in the region of the adductor muscle origin and radiating distally along the medial thigh. Needle electromyography demonstrates denervation of the adductor muscles. Surgical neurolysis treatment provides the definitive cure of this problem, with athletes returning to competition within several weeks of treatment. The surgical findings are entrapment of the obturator nerve by a thick fascia overlying the short adductor muscle. The role of conservative treatment in the management of this condition is unknown at present.

Chronic groin pain is a common and often disabling problem incurred by many athletes. Participation in sports in which repetitive kicking, side-to-side movement, and twisting are common motions seems to provide the greatest risk of causing this problem. The clinician encountering this condition may be confronted by a difficult diagnostic challenge because there are many potential causes of groin pain and many anatomic structures in the groin area that may be susceptible to injury or damage. Common causes of chronic groin pain in athletes include adductor muscle strain, stress fractures, osteitis pubis, psoas bursitis, and inguinal hernia.<sup>1, 5, 7, 19, 21, 26, 28</sup>

The purpose of this paper is to describe "obturator neuropathy," a previously undescribed syndrome of groin pain in athletes. We present 32 cases and describe the typical history, examination findings, investigation results, and management of this condition.

### ANATOMY

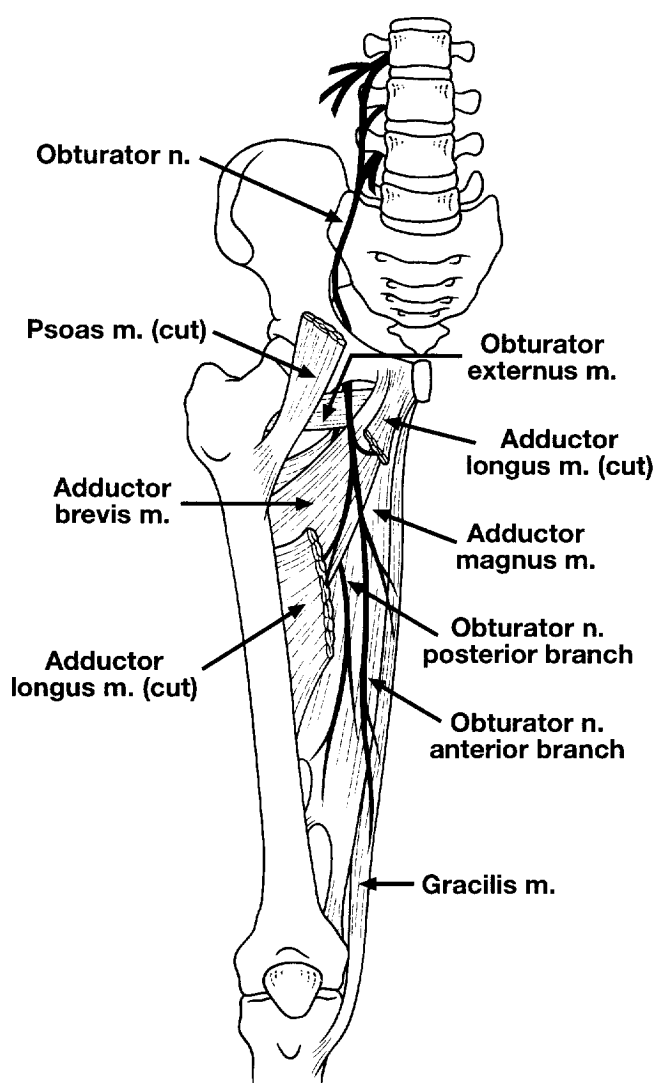
The obturator nerve arises from the anterior divisions of the ventral rami of the second, third, and fourth lumbar nerves (Fig. 1).<sup>37</sup> The rami unite within the substance of the psoas muscle and descend to emerge from its medial border at the level of the sacroiliac joint. The nerve runs over the pelvic brim into the lesser pelvis, curving antero-inferiorly and following the lateral pelvic wall to pass through a fibro-osseous tunnel. The obturator sulcus of the pubic bone forms the roof of this tunnel; the floor consists of the internal and external obturator muscles and their covering fascias.<sup>8</sup> Within the tunnel, the nerve divides into two main branches, as well as a branch to the external obturator muscle. At the distal end of the tunnel, the nerve passes through the obturator foramen to enter the thigh.

The anterior branch of the obturator nerve runs anterior to the external obturator and short adductor muscles and posterior to the pectineal and long adductor muscles. Near its origin, it gives off an articular branch to the hip joint. The anterior branch supplies the long and short adductor, gracilis, and, occasionally, the pectineal muscles. The anterior branch finally divides into cutaneous, vascular, and communicating branches. The cutaneous branch descends in the adductor canal to assist in the innervation of the skin and fascia of the distal two-thirds of the medial thigh.

The posterior branch of the obturator nerve pierces and supplies the external obturator muscle. The nerve then runs between the short and great adductor muscles and splits into a motor branch that supplies the great adductor muscle, and a sensory branch that descends through the adductor canal to the knee joint and perforates the oblique popliteal ligament to supply the articular capsule, cruciate ligaments, and synovial membrane of the knee joint.

\* Address correspondence and reprint requests to Dr. Paul McCrory, Olympic Park Sports Medicine Centre, Swan Street, Melbourne, Australia 3004.

No author or related institution has received financial benefit from research in this study.



**Figure 1.** Diagram of anatomy of the obturator nerve.

The accessory obturator nerve is an inconstant nerve that arises from L-3 and L-4. It has been estimated that this accessory obturator nerve occurs in 13% of normal persons.<sup>10,17</sup> When present, it descends along the medial border of the psoas muscle and crosses the superior pubic ramus to lie behind the pectineal muscle. It ends by helping to supply this muscle but may also supply branches to the hip joint.

#### LITERATURE REVIEW

The course of the obturator nerve places it at risk from disorders of all organ systems within the pelvis as well as from compression within the tunnel. Several studies have been published that give evidence of the problems related to the anatomic placement of this nerve. The nerve may be compressed within the true pelvis from pelvic fractures, pelvic hematomas secondary to anticoagulation<sup>35</sup> or trauma, retroperitoneal masses,<sup>23</sup> and intrapelvic tumors.

Complications may develop from normal life events such as pregnancy, which may lead to obstetrical obturator nerve palsy.<sup>3,24</sup>

While in the obturator tunnel, the nerve is well protected from direct trauma; however, complications of gynecologic or orthopaedic surgery may cause trauma to the nerve.<sup>32,38</sup> In addition, local inflammatory or infectious processes in the adjacent pubic bones may spread laterally to involve the region of the obturator foramen. Kopell and Thompson<sup>12</sup> and Leno et al.<sup>16</sup> have described an obturator tunnel syndrome related to inflammatory changes in osteitis pubis. No athletic or sports-related cases of obturator neuropathy or injury have been reported.

Other nerve entrapments in the inguinal region, such as entrapments of the genitofemoral<sup>29</sup> and ilioinguinal<sup>12</sup> nerves, may cause local pain and neurologic dysfunction that is anatomically distinct in location from obturator neuropathy. Other diagnostic possibilities include obturator hernias, which have been associated with obturator nerve entrapment. This entity is rare and difficult to diagnose but may respond to surgical intervention.<sup>9,14,15,22,34</sup>

#### METHODS

We treated 32 patients for obturator neuropathy over a 12-month period. The patients were divided into three groups for analysis (see "Patient Population" section). The sports in which the patients participated were Australian football (26 cases), soccer (2 cases), track (2 cases), and netball (1 case). One patient did not participate in sports. In the footballers and soccer players, there was no correlation of groin pain with their preferred kicking legs. Twenty-eight of the 29 patients included in the study were men. This may reflect a bias in patient selection because Australian rules football was the predominant sport involved or because there may be a distinct anatomic difference that puts men at increased risk of this problem.

Clinical symptoms and signs of postexercise medial thigh pain and adductor muscle weakness were present in all 29 patients. Paresthesia in the cutaneous distribution of the obturator nerve was present in 24 patients. Plain radiographic imaging studies showed normal results in 26 cases and demonstrated small ossicles in the region of the ipsilateral pubic tubercle in 3 cases. Technetium 99m radionuclide bone scanning was performed in 24 cases, of which 21 cases demonstrated mild isolated uptake on the ipsilateral pubic ramus in the region of the origins of the short and long adductor muscles. All patients had electromyographic evidence of denervation changes in the obturator nerve-innervated muscles.

#### Patient Population

*Group 1.* Group 1 consisted of 24 patients who had isolated obturator neuropathy—patients in whom the condition occurred without any antecedent injury or event—and who were treated by obturator nerve neurolysis. Group 1 consisted of 23 men and 1 woman with a mean age of 26.3 years (SD, 8.4). Ten patients experienced pain

on their right sides, 12 on their left sides, and 2 had bilateral pain. The mean duration of symptoms was 14 months (SD, 11.2).

**Group 2.** Group 2 consisted of five patients who had had concurrent inguinal hernia repairs performed at the time of their obturator neurolysis surgery. This was done because of clinical evidence of direct inguinal hernias in these patients. Four of the five men in Group 2 experienced groin pain on their left sides; the other patient had bilateral pain. Group 2 patients were examined significantly earlier (mean symptom duration,  $7.2 \pm 2.7$  months,  $P = 0.012$ ) and were older (mean age,  $30.8 \pm 13.7$  years,  $P = 0.52$ ). The earlier examination may be explained either by the fact that the additional abnormalities created more symptoms or it may be a reflection of the relatively small number of patients in this group.

**Group 3.** Group 3 consisted of three patients who had had previous groin surgery (adductor tenotomy, pubic symphysis curettage, and femoral nerve exploration) and in whom postsurgical fibrosis or scarring was considered to be the mechanism of nerve entrapment. Neurolysis surgery was successful in relieving obturator neuropathy symptoms in these cases.

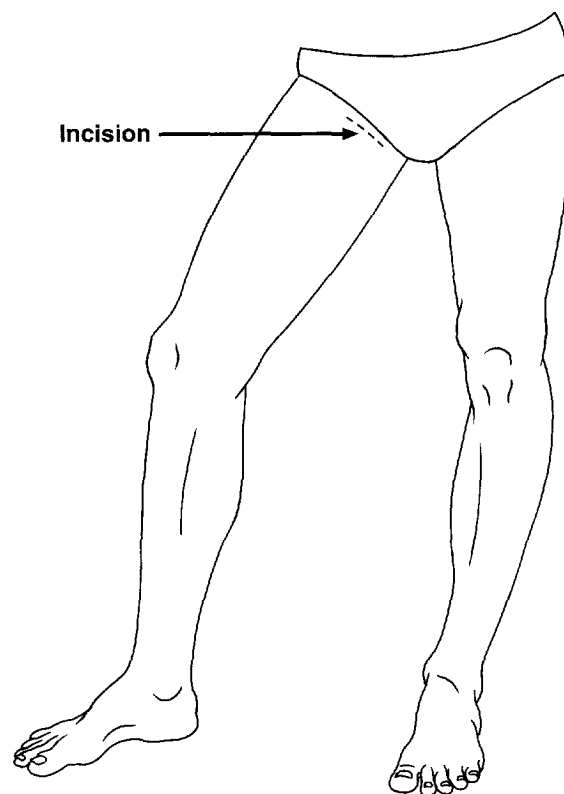
#### Surgical Technique

An oblique incision was made over the lateral aspect of long adductor muscle in the line of the inguinal crease. The incision commenced 1 cm distal to the pubic tubercle and was approximately 3 cm in length (Fig. 2). In the subcutaneous layer, the saphenous vein was retracted laterally. The tissues were stripped from the fascia overlying the long adductor and pectineal muscles and the fascia was divided along the lateral border of the long adductor muscle. Using blunt dissection, space was opened between these two muscles. The anterior branch of the nerve was seen to course over the short adductor muscle, lying under the thick fascia covering this muscle. The fascia was divided in the line of the nerve, with bipolar coagulation of fine vessels that coursed over the nerve.

The obturator nerve branches were then traced proximally under the pectineal muscle. If blood vessels from the medial circumflex femoral artery and vein are present, they need to be divided. The nerve was followed proximally to the foramen and was enlarged by insertion of the digit, being careful not to rupture any blood vessels in this region. The muscles were replaced in their normal position and the subcutaneous tissues and skin were closed.

#### Followup

We followed all patients for a mean of 23 months (SD, 2.4). During the follow-up period, one patient had a second episode of obturator neuropathy on the nonoperated side. This occurred after another unrelated surgical procedure (pubic symphysis curettage).



**Figure 2.** Location of surgical incision for obturator neurolysis.

#### RESULTS

Because there has been no previously published information on this condition, we will discuss typical findings of obturator neuropathy based on our study.

#### History of Pain

The pain has a typically insidious onset commencing as a deep ache centred on the adductor origin at the pubic bone; however, it is often difficult to precisely locate the pain. There may be also a referred pain in the region of the ipsilateral anterosuperior iliac spine. During exercise, the pain is more severe and may radiate down the medial aspect of the thigh toward the knee. The pain is typical of intermittent claudication and usually subsides with periods of rest but recurs on resumption of exercise. The patient may describe a sensation of exercise-induced weakness in the affected leg that is especially noticeable when attempting to jump off the affected leg. Numbness or paresthesia is seldom self-reported except in long-standing cases. Many patients with this pain have had previous groin surgery, usually consisting of inguinal hernia repair or adductor tenotomy, in an unsuccessful attempt to alleviate their chronic groin pain.

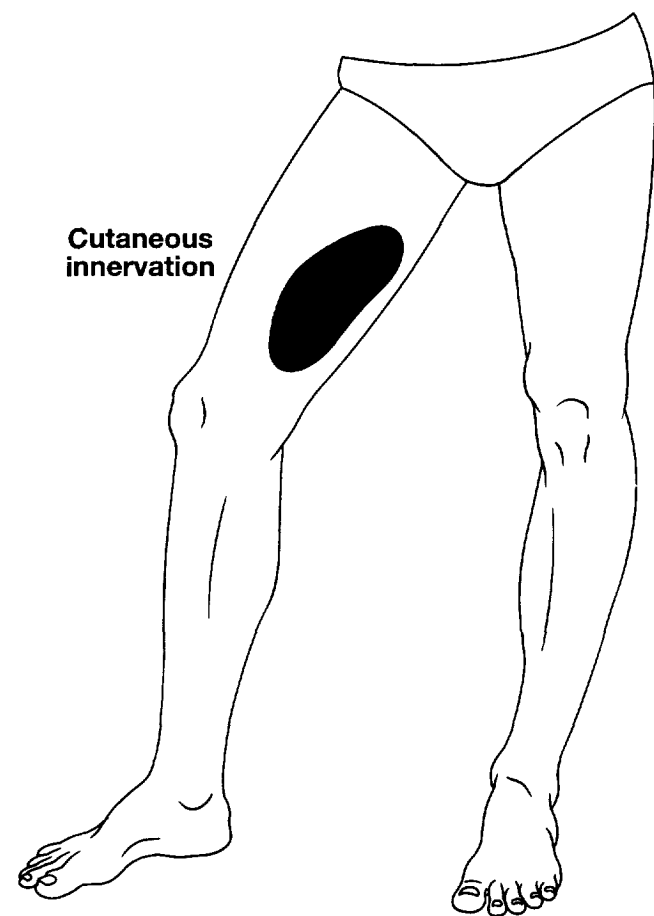
#### Examination Findings

The important thing to remember when examining patients with this condition is that many of the symptoms

may be present only after exercise. The most important specific signs are adductor muscle weakness, adductor muscle spasm, and paresthesia over the medial aspect of the distal thigh (Fig. 3). This weakness may not be complete, however, because the long and great adductor muscles receive partial innervation from the femoral and sciatic nerves, respectively. There is usually loss of adductor tendon reflex with preservation of the other deep tendon reflexes. Pain may be induced by a pectineal muscle stretch (which is performed by the patient passively externally rotating and abducting the affected hip while standing) or resisted hip internal rotation. Medial knee pain induced by forced hip abduction, extension, and internal rotation is known as Howship-Romberg's sign.<sup>27,31</sup>

#### Tests for Detection of Obturator Neuropathy

**Imaging.** Results of plain radiographic studies are usually normal, although there may be features of associated osteitis pubis. Magnetic resonance imaging may demonstrate atrophy of the muscles supplied by the anterior branch of the obturator nerve, i.e., the short and long adductor and gracilis muscles. No specific magnetic reso-



**Figure 3.** Diagram showing the cutaneous sensory distribution of the anterior branch of the obturator nerve in the medial thigh.

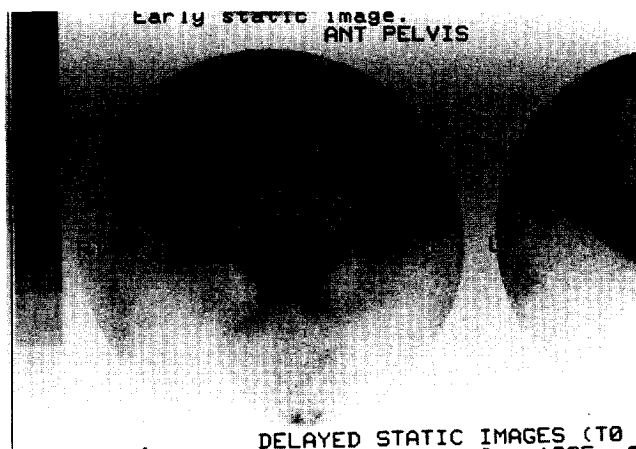
nance imaging abnormality of the nerve is evident either in the fibro-osseous tunnel or in the thigh. Scintigraphic bone scan frequently demonstrates a mild ipsilateral increase in uptake in the region of the pubic ramus, at the origin of the short or long adductor muscle, in the delayed phase of the scan. A typical scintigraphic finding is shown in Figure 4.

**Electrophysiology.** The most significant electrophysiologic changes are those of chronic denervation detected by needle EMG in the short and long adductor muscles.<sup>4</sup> We found denervation changes in all patients in our study. Paraspinal muscle sampling at L-2, L-3, and L-4 and in other muscles supplied by these nerve roots is normal, excluding a more proximal lesion. Nerve conduction studies of the other branches of the lumbosacral plexus were normal.

**Diagnostic Local Anesthetic Block.** The obturator nerve may be injected under fluoroscopic control at the obturator foramen using a local anesthetic agent such as lidocaine or bupivacaine.<sup>6,20</sup> A local anesthetic block of the nerve should reproduce the patient's postexercise weakness and should relieve the pain from the provocative stretches. Accurate localization and adequacy of the block can be assessed by noting the presence of paresthesia in the sensory distribution of the nerve over the distal medial thigh (Fig. 3). This test is useful to confirm the diagnosis before contemplating definitive surgical treatment. It is particularly useful when a coexisting diagnosis such as inguinal hernia or posterior inguinal wall weakness is being considered and the relative contribution of the obturator nerve entrapment to the overall symptoms needs to be assessed.

#### Treatment

**Conservative.** In our experience, conservative treatment methods have only limited success. In the more severe cases with electrophysiologic evidence of denervation, conservative treatment has been unsuccessful and definitive surgical intervention is preferred. The mean symptom



**Figure 4.** Typical scintigraphic bone scan appearance of obturator neuropathy (delayed phase of 99mTc bone scan).

duration before surgery was more than 12 months in these cases demonstrating that, in this group with more severe injury, conservative measures were ultimately unsuccessful. In patients with mild symptoms but without evidence of denervation findings on EMG, a conservative program may be attempted. In this group, we speculate that it may be possible by an aggressive conservative program to delay or avoid the progression to the more severe denervated state and hence avoid the need for operative intervention.

Conservative methods we tried included rest, physical therapy (such as ultrasound and interferential treatment), soft tissue massage, adductor muscle and pelvic strengthening exercises, oral antiinflammatory therapy, and groin stretches. Corticosteroid infiltration of the nerve at the level of the obturator foramen under fluoroscopic control was attempted in one of our patients with only transient benefit.

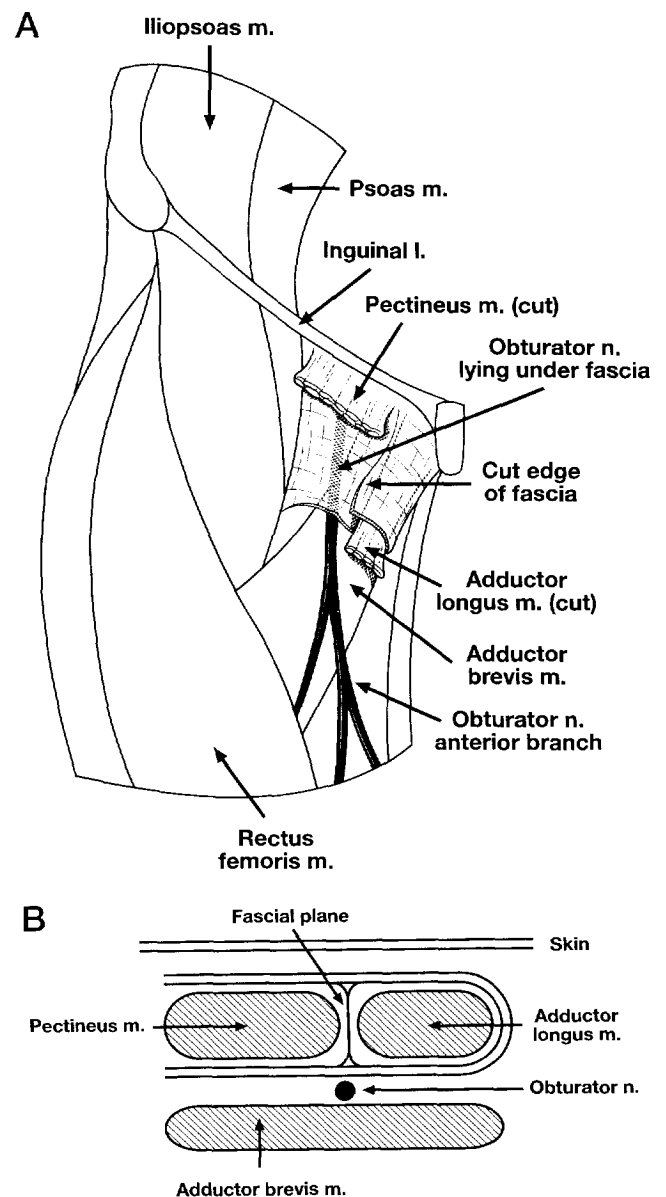
**Surgical.** Our surgical method is described under the "Methods" section. Postsurgical management was straightforward. Our early experience was fairly conservative, with limited activity for 6 weeks postoperatively. As our experience with the operation has increased, we now tend to be much more aggressive with our rehabilitation plan. The patients are instructed to walk within the limits of discomfort for the first 2 to 3 days after surgery and are then allowed to jog or run when pain-free. Most athletes find that within 1 week of the surgery they are able to run up to several kilometers or ride a bicycle without difficulty. A program of groin stretching and pelvic strengthening exercises is commenced. Correction of any underlying biomechanical abnormalities is achieved at this time. Physical therapy and local soft tissue massage should be considered in the postoperative phase. Resumption of training and return to sports is usually possible from between 3 to 6 weeks postoperatively. Our only complications of surgery have been local bruising in five cases and transient paresthesia in the sensory distribution of the obturator nerve in one case.

#### Outcome

Our study results were universally good, with all patients resuming full sporting participation without discomfort within 3 to 6 weeks. Patients in Groups 1 and 3 usually resumed sports within 2 to 3 weeks after surgery. Outcomes were assessed first by functional clinical testing during which it was found that all patients were free from any medial thigh pain or postexercise adductor weakness or numbness. Second, we performed repeat EMG analysis between 6 weeks and 12 months postoperatively, and in all patients the EMG recordings had returned to normal. Group 2 patients (with concurrent hernia repair) had a similar outcome; however, their return to full sporting participation was between 6 and 9 weeks after surgery.

#### PROPOSED PATHOPHYSIOLOGY

The mechanism of the entrapment resulting in obturator neuropathy is unclear. The clinical, electrophysiologic, and surgical findings suggest that the entrapment occurs



**Figure 5.** Fascial arrangement of the upper thigh. A, longitudinal diagrammatic view demonstrating the muscle and fascial arrangements of the obturator nerve. B, cross-sectional diagrammatic view parallel to the inguinal ligament at the level of the distal obturator foramen.

at the level of the obturator foramen and proximal thigh rather than in the obturator tunnel. The surgical findings of nerve entrapment by fascia and vessels over the external obturator and short adductor muscles may be the structural accompaniments of this entrapment.

Anatomic studies of the fascial arrangements in this region are singularly lacking.<sup>8,30</sup> We performed six cadaveric dissections of this region and noted that the fascia overlying the short adductor muscle is separate from the intermuscular fascial septa and is not described in any of the anatomy textbooks as a distinct layer<sup>30,37</sup> (Fig. 5). We

believe that mechanical restriction of the nerve by this fascial layer is the basis for this condition. In addition, the difference in the bony pelvic anatomy between the sexes may contribute to the marked sexual difference in incidence. Men have higher ilial bones, a smaller transverse diameter of the pelvic inlet, and a narrower subpubic angle, which may alter the angle at which the nerve passes through the lesser pelvis and create a greater bend in the nerve in the obturator canal. Fascial restriction at this level may then be exacerbated by biomechanical abnormalities.

Other authors writing about myofascial conditions have attributed localized adductor pain to "trigger points" that secondarily generate increased tension in the adductor muscle complex.<sup>11,18,33,36</sup> Travell and Simons<sup>36</sup> state that trigger point involvement of the long adductor muscle is "perhaps the most common cause of groin pain." Interestingly, they suggest a number of treatment strategies including "cold and stretch" and "injection and stretch" that they have found helpful for this problem. The local anesthetic injection they use is similar to the obturator block we describe and at least one of their patients who responded to this mode of therapy had a clear-cut obturator block with the associated paresthesia. We suspect that the trigger point abnormalities they describe may have their origin as an entrapment of the obturator nerve. Travell and Simons propose a conservative management strategy that may be worth considering in these cases.

In some of our patients, symptoms of inguinal hernia preceded the development of the obturator neuropathy symptoms, and the possibility of a mechanical stretching of the nerve either from the hernia or secondary to biomechanical alteration in running patterns is possible. These patients may be predisposed to the development of this problem by a fascial restriction of the obturator nerve. Of interest is the observation that previously, at least in Australia, inguinal hernia repair has been a common surgical management for athletes with chronic groin pain. In the absence of frank herniation, muscular weakness of the posterior wall of the inguinal canal has been proposed as the mechanism of pain, and surgical intervention to repair this structure has been proposed.<sup>28</sup>

The bone scan findings of ipsilateral increased uptake over the pubic tubercle and inferior pubic ramus may imply an underlying inflammatory basis that then tracks along the fascia to entrap the nerve secondarily (Fig. 4). More likely, muscular tightness, as evidenced by the clinical sign of adductor muscle spasm, results in biomechanical dysfunction, which in turn leads to a localized tenosynovitis, giving the characteristic bone scan appearance. There are several case reports of entities such as "thigh splints" and adductor insertion stress fractures that have a similar bone scan appearance.<sup>2,25</sup> These cases share a number of similarities in their clinical presentations to our cases. It is possible that these periosteal changes, if they become chronic, may be a precursor of the condition of osteitis pubis.

In our three reported cases of patients with previous surgery (Group 3 patients), local scar tissue formation was found to entrap the nerve at the same level. In the patient

who had a pubic symphysis curettage, the athlete was aware of unilateral obturator neuropathy symptoms as soon as he awoke from the anesthetic. This patient had had obturator neuropathy on the opposite side 18 months before and he thought that the pain was identical to his previous symptoms. The postsurgical obturator neuropathy symptoms were persistent despite conservative therapy (including nonsteroidal antiinflammatory treatment) and were ultimately relieved successfully by an obturator nerve neurolysis.

## SUMMARY

We propose that obturator neuropathy is a previously unreported cause of chronic groin pain. This condition has a characteristic clinical pattern. We emphasize that patients should be examined after exercise as well as at rest. The diagnosis may be made by electrophysiologic studies and confirmed by obturator nerve block with local anesthetic. The findings of the characteristic bone scan appearance may help confirm the clinical suspicion of this condition. The definitive treatment is surgical, but conservative measures need to be considered. We suggest that obturator neuropathy is a form of focal nerve entrapment by fascial or vascular structures or both, but there may be an inflammatory or fibrotic basis in some cases.

## REFERENCES

1. Brukner P, Khan KM: *Clinical Sports Medicine*. Sydney, McGraw-Hill, 1993, pp 302-315
2. Charkes ND, Siddhivam N, Schneck CD: Bone scanning in the adductor insertion avulsion syndrome ("thigh splints"). *J Nucl Med* 28: 1835-1838, 1987
3. Clark JMP: Obstetrical palsy. *J Bone Joint Surg* 47B: 806, 1965
4. Delagi EF, Perotto A: *Anatomic Guide for the Electromyographer*. Second edition. Springfield, Charles C Thomas Publishers, 1980
5. Ekberg O, Persson NH, Abrahamsson PA: Longstanding groin pain in athletes: A multidisciplinary approach. *Sports Med* 6: 56-61, 1988
6. Felsenthal G: Nerve blocks in the lower extremities: Anatomical considerations. *Arch Med Phys Rehabil* 55: 504-507, 1974
7. Fricker PA, Taunton JE, Ammann W: Osteitis pubis in athletes: Infection, inflammation or injury? *Sports Med* 12: 266-279, 1991
8. Gerlach UJ, Lieser W: Functional construction of the superficial and deep fascia system of the lower limb in man. *Acta Anat* 139: 11-25, 1990
9. Hannington-Kiff JG: Absent thigh adductor reflex in obturator hernia. *Lancet* 1: 180, 1980
10. Katritsis E, Anagnostopoulou S, Papadopoulos N: Anatomical observations in the accessory obturator nerve (based on 1000 specimens). *Anat Anz* 148: 140-145, 1980
11. Kelly M: Some rules for the employment of local analgesia in the treatment of somatic pain. *Med J Aust* 1: 235-239, 1947
12. Kopell HP, Thompson W: Peripheral entrapment neuropathies of the lower extremity. *N Eng J Med* 262: 56, 1960
13. Kopell HP, Thompson WA, Postell AH: Entrapment neuropathy of the ilioinguinal nerve. *New Eng J Med* 266: 16-19, 1962
14. Kozlowski JM, Beal JM: Obturator hernia: An elusive diagnosis. *Arch Surg* 112: 1001-1002, 1977
15. Larrieu AJ, De Marco SJ: Obturator hernia: Report of a case and brief review of its status. *Am Surg* 42: 273-277, 1976
16. Leno C, Combarros O, Polo JM, et al: Bilateral obturator neuralgia secondary to osteitis of the pubis. *Arch Neurobiol* 47: 347-352, 1984
17. Lolic-Draganic V, Ilic A: Obturator nerve. *Acta Orthop Lugosl* 3: 361-363, 1972
18. Long C: Myofascial pain syndromes. *Henry Ford Hosp Med Bull* 4: 102-106, 1956
19. Lovell G: The diagnosis of chronic groin pain in athletes: An evaluation of 189 cases. *Aust J Sci Med Sport* 27: 76-79, 1995
20. Magora F, Rozin R, Ben-Menachem Y, et al: Obturator nerve block. An evaluation of technique. *Br J Anaesth* 41: 695-698, 1969

21. Martens MA, Hansen L, Mulier JC: Adductor tendonitis and musculus rectus abdominus tendonopathy. *Am J Sports Med* 15: 353-356, 1987
22. Martin NC, Welch TP: Obturator hernia. *Br J Surg* 61: 547-548, 1974
23. Missoul C: Nerve Injuries, in Dee R (ed): *Principles of Orthopaedic Practice*. New York, McGraw-Hill, 1989
24. Oppenheim H: *Lehrbuch der Nervenkrankheiten*. Berlin, S. Karger, 1923, pp 458-459
25. Oxburn MS, Nichols JW: Pubic ramus and adductor insertion stress fractures in female basic trainees. *Milit Med* 146: 332-334, 1981
26. Pavlov H, Nelson TL, Warren RF, et al: Stress fractures of the pubic ramus. A report of twelve cases. *J Bone Joint Surg* 64A: 1020-1025, 1982
27. Pecina MM, Krmpotic-Nemanic J, Markiewitz AD: *Tunnel Syndromes*. Boca Raton, FL, CRC Press, 1991 pp 93-97
28. Polglase AL, Frydman GM, Farmer KC: Inguinal surgery for debilitating chronic groin pain in athletes. *Med J Aust* 155: 674-677, 1991
29. Rischbeith RH: Genitofemoral neuropathy. *Clin Exp Neurol* 22: 145-147, 1986
30. Romanes GJ: *Cunningham's Manual of Practical Anatomy*. London, Oxford University Press, 1976, pp 106-119
31. Saurenmann P, Brand S: Obturatorius neuralgie (Howship-Romberg phenomenon). *Schweiz Med Wochenschr* 114: 1462-1464, 1984
32. Siliski JM, Scott RD: Obturator nerve palsy resulting from intra-pelvic extrusion of cement during total hip replacement. Report of four cases. *J Bone Joint Surg* 67A: 1225-1230, 1985
33. Simons DG: Myofascial pain syndrome due to trigger points, in Goodgold J (ed): *Rehabilitation Medicine*. St Louis, CV Mosby Co, 1988, pp 686-723
34. Somell A, Ljungdahl I, Spangen L: Thigh neuralgia as a symptom of obturator hernia. *Acta Chir Scand* 142: 457-459, 1976
35. Susens GP, Hendrikson CG, Mulder J, et al: Femoral nerve entrapment secondary to a heparin hematoma. *Ann Intern Med* 69: 575-579, 1968
36. Travell J, Simons DG: *Myofascial Pain and Dysfunction: Volume 2. The Lower Extremities*. Baltimore, Williams & Wilkins, 1992, pp 289-314
37. Warwick R, Williams RL (eds): *Gray's Anatomy*. Thirty-fifth edition. Edinburgh, Longman Group Publishers, 1973, pp 1052-1053
38. Weber ER, Daube JR, Coventry MB: Peripheral neuropathies associated with total hip arthroplasty. *J Bone Joint Surg* 58A: 66-69, 1976