

Stuart J. Warden
Hayden G. Morris
Kay M. Crossley
Peter D. Brukner
Kim L. Bennell

Delayed- and non-union following opening wedge high tibial osteotomy: surgeons' results from 182 completed cases

Received: 30 May 2003
Accepted: 4 October 2003
Published online: 22 April 2004
© Springer-Verlag 2004

S. J. Warden · H. G. Morris
K. M. Crossley · P. D. Brukner
K. L. Bennell
Centre for Health,
Exercise and Sports Medicine,
School of Physiotherapy,
University of Melbourne,
Parkville, Victoria, Australia

S. J. Warden (✉)
Department of Orthopaedic Surgery,
School of Medicine, Indiana University,
1120 South Drive,
Indianapolis, IN 46202, USA
Tel.: +1-317-2789573,
Fax: +1-317-2789568,
e-mail: stwarden@iupui.edu

Abstract Opening wedge high tibial osteotomy (OWHTO) is a recently described procedure for medial compartment arthritis of the knee in the active, younger population. Despite having a number of advantages over the traditional closing wedge high tibial osteotomy (CWHTO) a potential complication of OWHTO is a high rate of delayed- and non-union. This study reports the occurrence of delayed- and non-union following OWHTO for medial compartment arthritis of the knee. Questionnaires were sent to all current members of the Australian Knee Society ($n=45$), a special interest group of the Australian Orthopaedic Group. Surgeons were asked primarily to indicate how many OWHTOs they had performed,

and how many of these had progressed to union, delayed-union and non-union. All 45 questionnaires were returned, with 21 surgeons (47%) performing OWHTOs. A total of 188 OWHTO cases were reported, of which 182 were complete. Of these complete cases 167 (91.8%) were classed as united, 12 (6.6%) delay-united and 3 (1.6%) non-united. The results of this study demonstrate that the rate of delayed- and non-union following OWHTO for medial compartment arthritis of the knee is relatively low and comparable to that reported for traditional CWHTO.

Keywords Fracture fixation · Knee · Orthopedics · Osteoarthritis · Osteotomy

Introduction

The standard operative treatment for medial compartment arthritis of the knee in the active, young population is a closed wedge high tibial osteotomy (CWHTO) [6, 9]. A CWHTO involves the removal of a wedge of bone from the proximal tibia to create an angled gap. Closing of the vacant wedge restores the mechanical axis of the knee joint to correct abnormal loading and provide symptomatic relief from arthritis without the activity restrictions imposed by knee replacement [3]. However, the CWHTO is associated with drawbacks. The surgery is technically demanding, often requiring multiple bone incisions to generate the desired degree of correction, and there is disruption of the proximal tibiofibular joint and the potential for neurovascular complication [1]. The performance of a CWHTO also reduces tibial bone stock and

has implications for future conversion to knee replacement [8, 13].

Due to drawbacks with the CWHTO technique a technique for opening wedge high tibial osteotomy (OWHTO) has more recently been described [5, 7, 11]. This involves making a single cut across the proximal tibia and opening a wedge. The vacant wedge is filled and stabilised with a stainless steel plate (Fig. 1). The OWHTO has a number of advantages over the CWHTO technique [6, 7]. It is faster and simpler to perform. This results from the need for only one bone incision and the intra-operative ability to alter the extent of correction without additional incisions. There is no surgical disruption of the proximal tibiofibular joint and reduced risk of neurovascular complication [7]. OWHTO also appears to allow easier conversion to knee replacement [7, 10]. Despite these advantages potential disadvantages of the OWHTO are high rates of delayed- and non-union [4, 6]. The aim of this

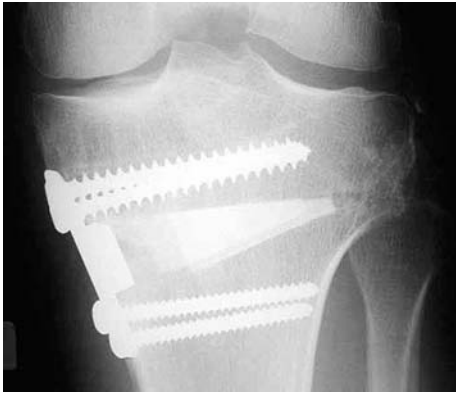

Fig. 1 Postoperative radiograph of an opening wedge high tibial osteotomy in a 42-year-old man. The osteotomy was filled with a tricalcium wedge and fixed with an Arthrex-Puddu plate

study was to report the occurrence of delayed- and non-union following OWHTO for medial compartment arthritis of the knee.

Materials and methods

Following ethical approval (Human Research Ethics Committee, University of Melbourne) questionnaires were sent to all current members of the Australian Knee Society, a special interest group of the Australian Orthopaedic Association. A total of 45 members were on the membership list at the time of study. Completion and subsequent return of the questionnaire signified surgeon consent to participate and questionnaires were blindly returned. The questionnaire asked whether surgeons had performed OWHTOs. Surgeons who perform OWHTO were asked to indicate how many they had performed, which induction or conduction agents they use, how large a wedge they are prepared to open, which fixation devices they use, and what their post-operative weight bearing protocol is. For each of their cases surgeons were asked to indicate how many fell into the following categories: (a) united, united in less than 3

months, (b) delayed-union, united in 3–6 months, (c) non-union, not united within 6 months, and (d) incomplete, patients who have recently undergone surgery (less than 3 months ago) and are yet to unite. Surgeons used their own clinical and radiographical criteria to determine union. Finally, surgeons were asked to report what they feel the advantages and disadvantages of OWHTO are compared with CWHTO, and state whether they feel that OWHTO has advantages over CWHTO either all of the time, some of the time or never.

Results

All 45 questionnaires (100%) were returned, with 21 surgeons (47%) performing OWHTOs. A total of 188 OWHTO cases were reported, of which 182 were complete. Of these completed cases 167 (91.8%) were classed as united, 12 (6.6%) delay-united and 3 (1.6%) non-united (Fig. 2). The occurrence of delayed- and non-union with different conduction/induction agents is shown in Table 1. The most frequently used agents were iliac crest bone grafts, which were used in 69% of completed cases by 10 surgeons (48%). These were followed by coral wedges, which were used by 6 surgeons (29%) in 15% of completed cases. During surgery 12 surgeons (57%, who had 120 completed OWHTO cases) were prepared to open a wedge with a maximal medial tibial gap of 15 mm. The remaining nine surgeons (43%, who had 62 completed cases) were prepared to open a maximal medial tibial gap of 20 mm. To stabilise the osteotomy site 12 surgeons (57%) used Arthrex-Puddu plates, five (24%) used Smith and Nephew Cross plates, three (14%) used A-O plates, and one (5%) used buttress plates. The occurrence of delayed- and non-union with the different fixation devices is shown in Table 2. Following OWHTO, patients are kept non-weight bearing by 14 surgeons (67%, who had 122 completed cases) for between 4 and 8 weeks. Five surgeons (24%, who had 49 completed cases) keep patients partial weight bearing for

Fig. 2a,b Example of non-union of an opening wedge high tibial osteotomy in a 41-year-old woman. The osteotomy was filled with a tricalcium wedge and fixed with a Arthrex-Puddu plate. **a** There is extension of the osteotomy through the lateral cortex and a lateral gap of 3–4 mm surrounded by sclerosis. The screws went on to break and position was lost resulting in recurrent varus. **b** Outcome of revision surgery. A bone graft and a second plate were used resulting in union and an excellent outcome. Note the broken screw on the original Arthrex-Puddu plate

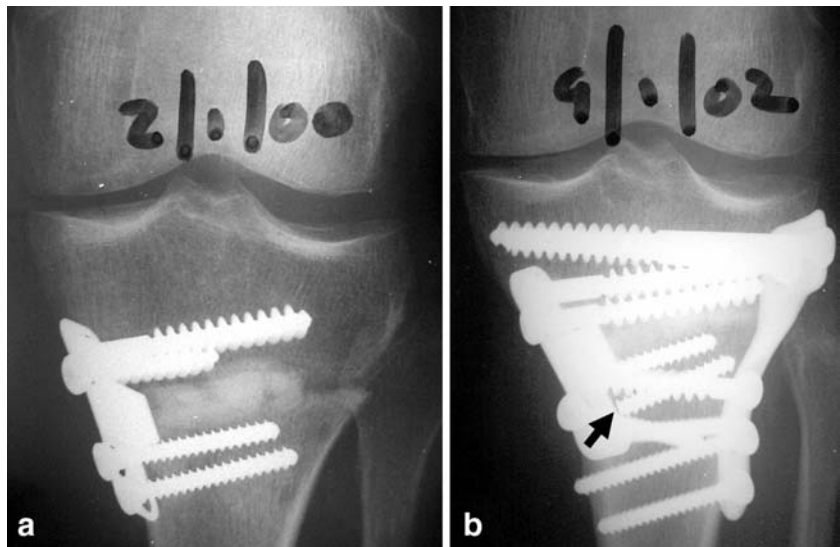


Table 1 Delayed- and non-union reported with each induction/conduction agent

Induction/conduction agent	United (n=167)	Delayed-union (n=12)	Non-union (n=3)	Incomplete (n=6)
Iliac crest bone graft	117	8	–	3
Coral wedges	23	3	1	3
Hatric bone substitute	16	–	–	–
Iliac crest bone graft, coral wedges	2	1	–	–
Iliac crest bone graft, CaSO ₄ beads	3	–	2	–
No induction/conduction agent	6	–	–	–

Table 2 Delayed- and non-union reported with each fixation device

Device	United (n=167)	Delayed-union (n=12)	Non-union (n=3)	Incomplete (n=6)
Arthrex-Puddu plate	107	4	3	3
Smith and Nephew Cross plate	23	7	–	3
Buttress plate	24	1	–	–
A-O L or T plate	8	–	–	–
Device not reported	5	–	–	–

Table 3 Reported advantages and disadvantages of OWHTO compared with CWHTO

		n	%
Advantages	Simplicity	15	71
	Better control of degree of opening	12	57
	Biomechanics	11	52
	Better able to control AP opening	9	43
	Avoid loosening of lateral side	8	38
	Smaller incision	8	38
	No fibular involvement	3	14
	Other ^a	5	24
Disadvantages	Bone graft harvest morbidity	15	71
	Delayed-/non-union	10	48
	Time non-weight bearing	8	38
	Combined procedures	3	14
	Other ^b	5	24

^aIncluding better later conversion to total knee replacement, no neural complications, preservation of bone stock, tightening of medial collateral ligament and larger wedge possible

^bLoss of correction, loss of control of proximal segment (X2), limb lengthening and posterior tibial slope

between 3 and 6 weeks, whilst the remaining two surgeons (9%, who had 11 completed cases) keep patients partial weight bearing until union. The reported advantages and disadvantages of the OWHTO compared with CWHTO are shown in Table 3. Overall, six surgeons (29%, who had 80 completed cases) considered OWHTO to have advantages over CWHTO all of the time, whereas the remaining 15 (71%, who had 102 completed cases) felt that OWHTOs had advantages only some of the time.

Discussion

The results of this study demonstrate that the rates of delayed- and non-union following OWHTO for medial compartment arthritis of the knee are relatively low. The occurrences of delayed- and non-union were 6.6% and 1.6%, respectively. These compare favourably with the respective rates of delayed- and non-union of 8.5% and 0.5–5.7% observed with traditional CWHTOs [2, 12]. The current findings suggest that delayed- and non-union are not prominent complications following OWHTO. This is important information to convey to both patients and surgeons for pre-operative consideration. Delayed- and non-union during bone repair are undesirable outcomes, and they are of particular concern when they occur following a surgically induced bone injury such as OWHTO. Delayed- and non-union following OWHTO have previously been suggested to be disadvantages of this technique [4, 6], with 48% of surgeons in the current study reporting as such.

This study consisted of a retrospective surgeon questionnaire, and demographic data on individual patients were not gathered. Consequently it is not possible to determine whether patients who exhibited delayed- or non-union possessed co-morbidities or co-existing factors that may have influenced their post-operative bone repair. Similarly, given the study design it cannot be determined whether particular features of the surgical procedure performed contributed to delayed- or non-union. However, given the overall low rates of delayed- and non-union reported, these are not limitations of the study. Low rates were found despite surgeons using a range of induction/conduction agents, fixation devices, post-operative weight bearing protocols and presumably surgical techniques. These low rates observed in a relatively large group of surgeons and patients suggests that OWHTO is a rela-

tively robust technique that can withstand individual surgeon and patient idiosyncrasies. However, it must be highlighted that surgeons unblindly reviewed their own patient radiographs potentially biasing the results. Similarly, it is possible that the results were biased through amenable patient selection. Future prospective trials with independent blind assessors and known inclusion and exclusion criteria should address these limitations.

As the sole aim of the current investigation was to report the occurrence of delayed- and non-union following OWHTO, the occurrence of other complications associated with this procedure were not investigated. One potential complication is donor site morbidity [6, 7]. Iliac crest bone grafts were found to be the commonly used space-filling agent during OWHTO. Although delayed- and non-union following OWHTO were not found to be prominent complications of this procedure, it is possible that donor site morbidity may minimise the overall benefits of performing a OWHTO. Supporting this, 71% of surgeons considered donor site morbidity to be a disadvantage of the OWHTO technique. Future prospective investigations should focus on this and other factors that may influence the comparative advantages of the OWHTO technique over that of the traditional CWHTO.

In summary, this study found that, contrary to anecdotal reports, the occurrences of delayed- and non-union following OWHTO are relatively low and appear comparable with the rates reported for traditional CWHTO. However, this finding is limited in that surgeons unblindly reviewed their own radiographs, and patient selection criteria are not known. Further prospective trials are required to validate the current findings. In the meantime the results of this preliminary study provide initial valuable information for both surgeons and patients to consider when making pre-operative decisions regarding the management of medial compartment arthritis of the knee.

Acknowledgements The authors thank all members of the Australian Knee Society, a special interest group of the Australian Orthopaedic Association, for their completion of the questionnaire. This work was presented at the Combined New Zealand and Australian Knee and Sports Surgery Society Meeting in Queenstown, New Zealand, October 2001. S.J.W. holds a National Health and Medical Research Council (Australia) CJ Martin Fellowship (Regkey no. 209169). K.M.C. holds a National Health and Medical Research Council (Australia) Health Professional Training Fellowship (Regkey no. 209168).

References

1. Aydogdu S, Cullu E, Arac N, Varolgunes N, Sur H (2000) Prolonged peroneal nerve dysfunction after high tibial osteotomy: pre- and postoperative electrophysiological study. *Knee Surg Sports Traumatol Arthrosc* 8:305–308
2. Cameron HU, Welsh RP, Jung Y-B, Noftall F (1993) Repair of nonunion of tibial osteotomy. *Clin Orthop* 287:167–169
3. Dowdy PA, Cole BJ, Harner CD (1998) Knee arthritis in active individuals: matching treatment to the diagnosis. *Physician Sportsmed* 26:43–54
4. Fowler PJ (2001) The role of osteotomy in the post-meniscectomy knee: an open or closed case. Presented at the American Academy of Orthopaedic Surgeons 68th Annual Meeting, San Francisco, CA
5. Fowler PJ, Tan JL, Brown GA (2000) Medial opening wedge high tibial osteotomy: how do I do it? *Oper Tech Sports Med* 8:32–38
6. Hart JAL, Sekel R (2002) Osteotomy of the knee: is there a seat at the table? *J Arthroplasty* 4 [Suppl 1]:45–49
7. Hernigou P, Ma W (2001) Open wedge tibial osteotomy with acrylic bone cement as bone substitute. *Knee* 8:103–110
8. Karabatsos B, Mahomed NN, Maistrelli GL (2002) Functional outcome of total knee arthroplasty after high tibial osteotomy. *Can J Surg* 45:116–119
9. Kharrazi D, Chandler RW, Spitzer AI (2000) High tibial osteotomy for the treatment of unicompartmental arthritis of the knee. *Curr Opin Orthop* 11:26–34
10. Kitson J, Weale AE, Lee AS, Maceachern AG (2001) Patellar tendon length following opening wedge high tibial osteotomy using an external fixator with particular reference to later total knee replacement. *Injury* 32:S-D-140–143
11. Koshino T, Murase T, Saito T (2003) Medial opening-wedge high tibial osteotomy with use of porous hydroxyapatite to treat medial compartment osteoarthritis of the knee. *J Bone Joint Surg [Am]* 85:78–85
12. Naudie D, Bourne RB, Rorabeck CH, Bourne TJ (1999) Survivorship of the high tibial valgus osteotomy: a 10- to 22-year followup study. *Clin Orthop* 367:18–27
13. Nizard RS, Cardinne L, Bizot P, Witvoet J (1998) Total knee replacement after failed tibial osteotomy: results of a matched-pair study. *J Arthroplasty* 13:847–853